

Case presentation



Challenging Lead Insertion

Dr /Taymour Abdelhaleem
Egyption fellowship of Electrophysiology

History



- ☞ Male pt ,43 y old , not known to be DM or HTN.
- ☞ At age of 8 years old diagnosed as Congenital CHB , with conservative and follow up plan .
- ☞ At age of 23 y old decision taken to insert dual lead PPM.
- ☞ 10 years later battery replacement done.

History



- ❧ 4 years later for reason not clear (mostly related to leads), another dual PPM inserted in the same left subclavicular side , leaving the old both leads without extraction.
- ❧ That procedure complicated with pocket haematoma which was resolved spontaneously with medical treatment.
- ❧ After that pt doing well for 5 years .

History



- ❧ The patient presented in NHI outpatient clinic with severe pocket infection.
- ❧ Echo done show lead vegetations, mild TR , mod MR, dilated LV, otherwise no other abnormalities
- ❧ TEE done confirm two masses seen attached to RV lead at RA level.

History



- ❧ Pt admitted for aggressive medical therapy
- ❧ Cardiac surgery referral done
- ❧ Whole system including old leads surgically removed , epicardial Temporary pacing secured.
- ❧ Smooth post operative course, pt doing well, blood tests and cultures good

History

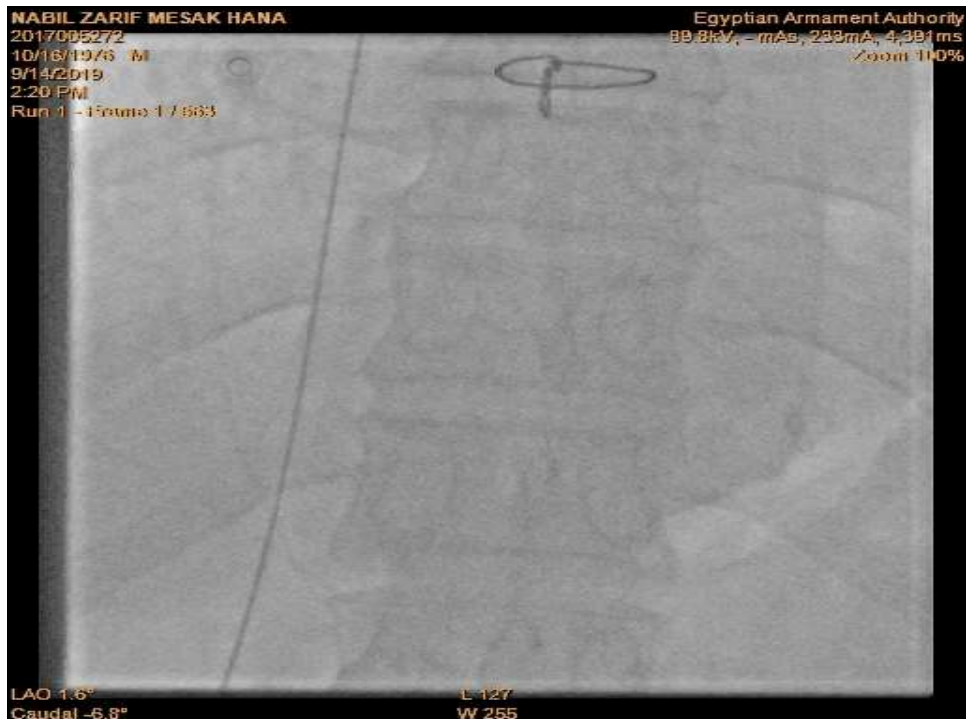

- ❧ Post operative Echo show no significant changes from the previous one regarding mild TR , Mod MR,Dilated LV.
- ❧ 2 months later Decision taken to insert new single lead PPM at Rt subclavicular region (as ECG show At flutter).
- ❧ Pt prepared and procedure started

In Cath-Lab



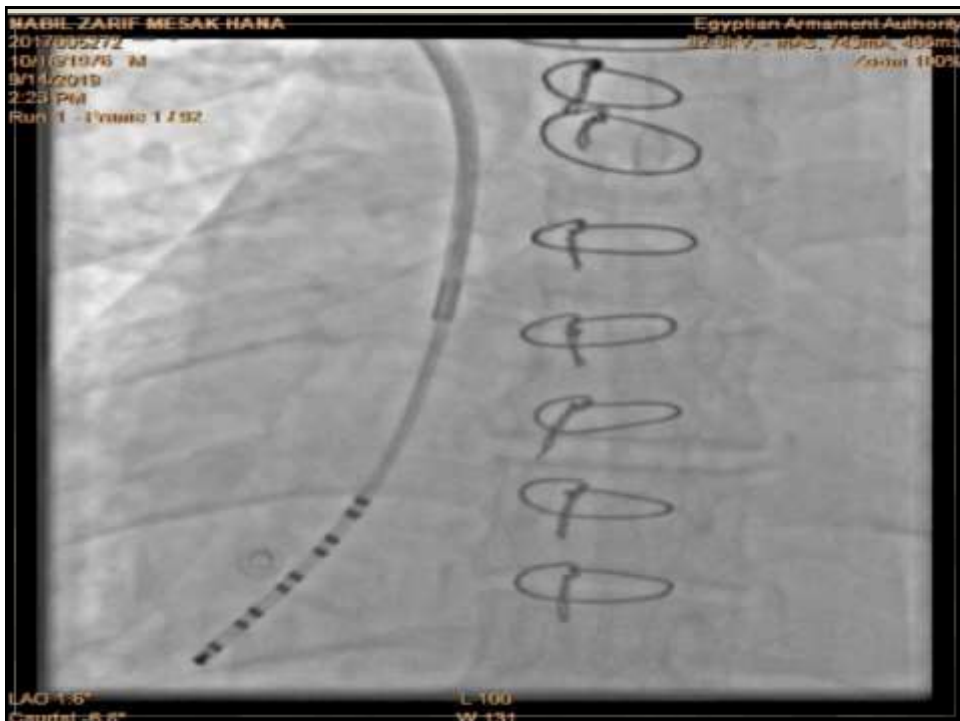- ⌘ Around 3 hours of trials and negotiation to pass Tricuspid valve and insert the lead unfortunately failed.
- ⌘ So strategy changed to insert LV lead through coronary sinus



In Cath-Lab



⌘ Again another 1 hour of trials to enter coronary sinus but unfortunately failed also.



In Cath-Lab



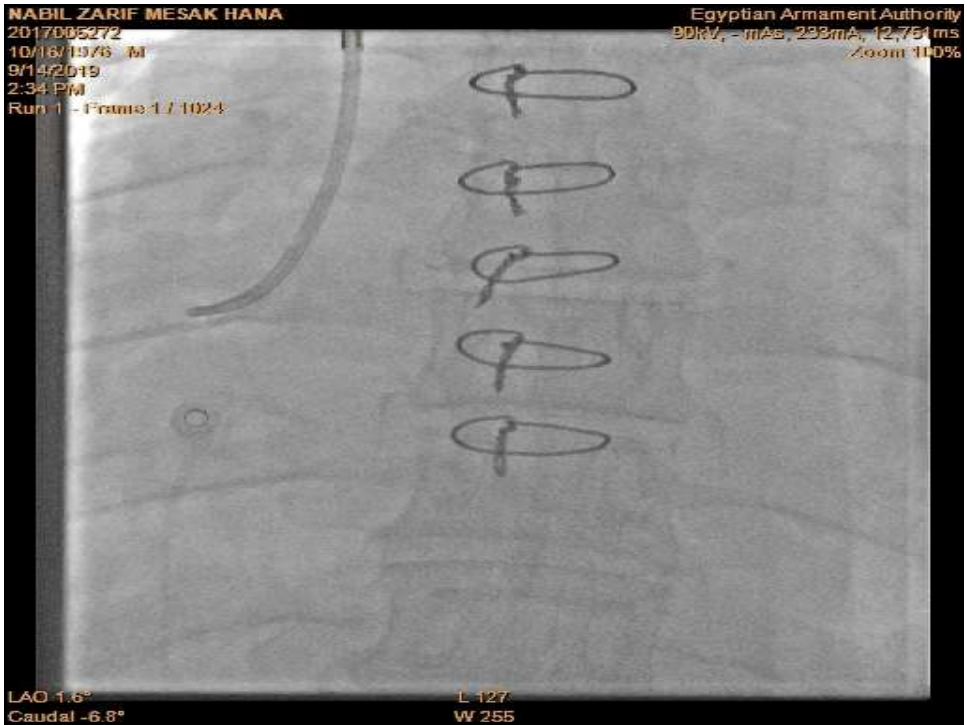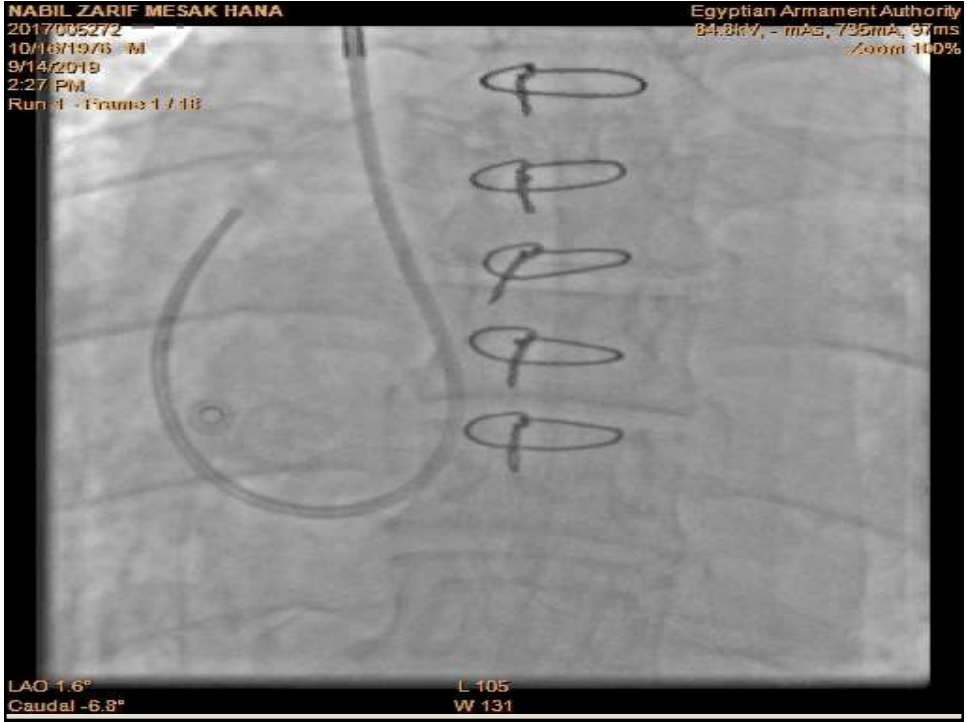☞ So the question now what we can do else???

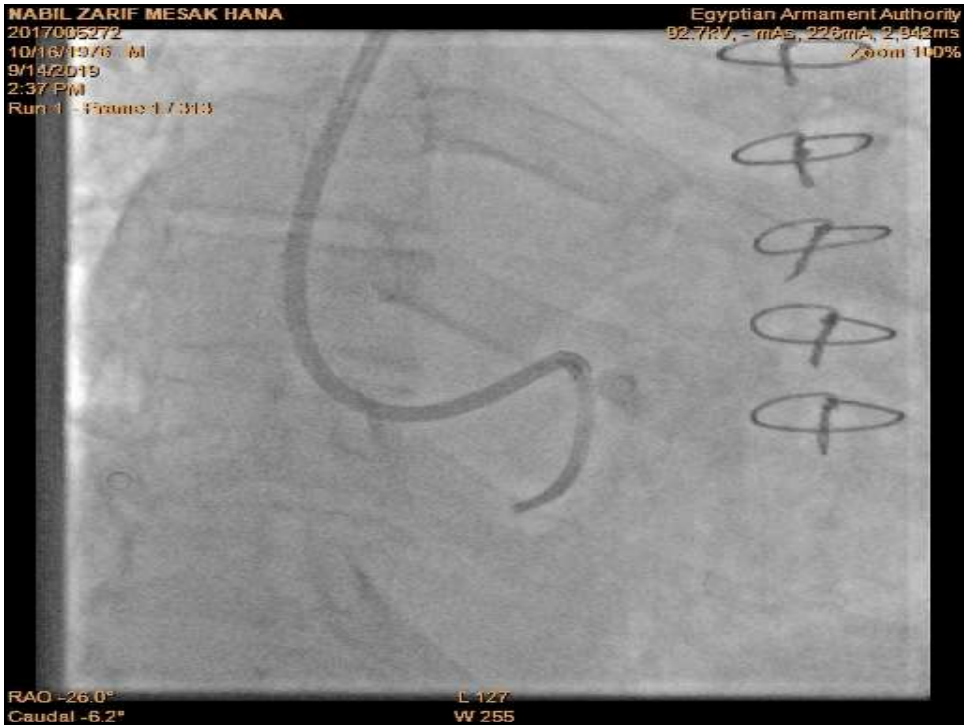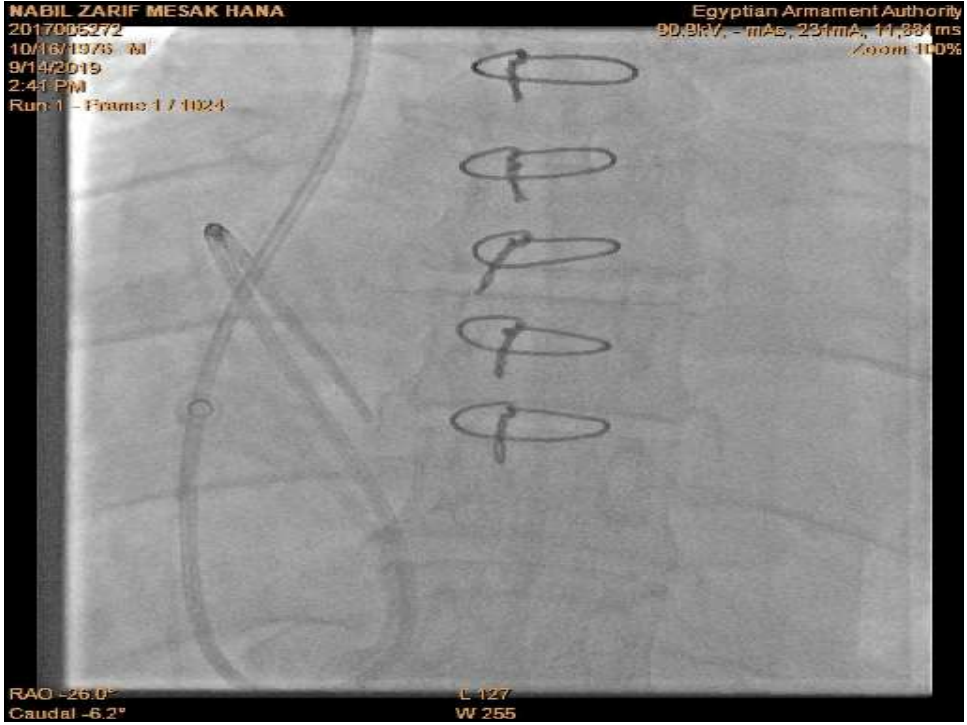☞ Can anything else help?????

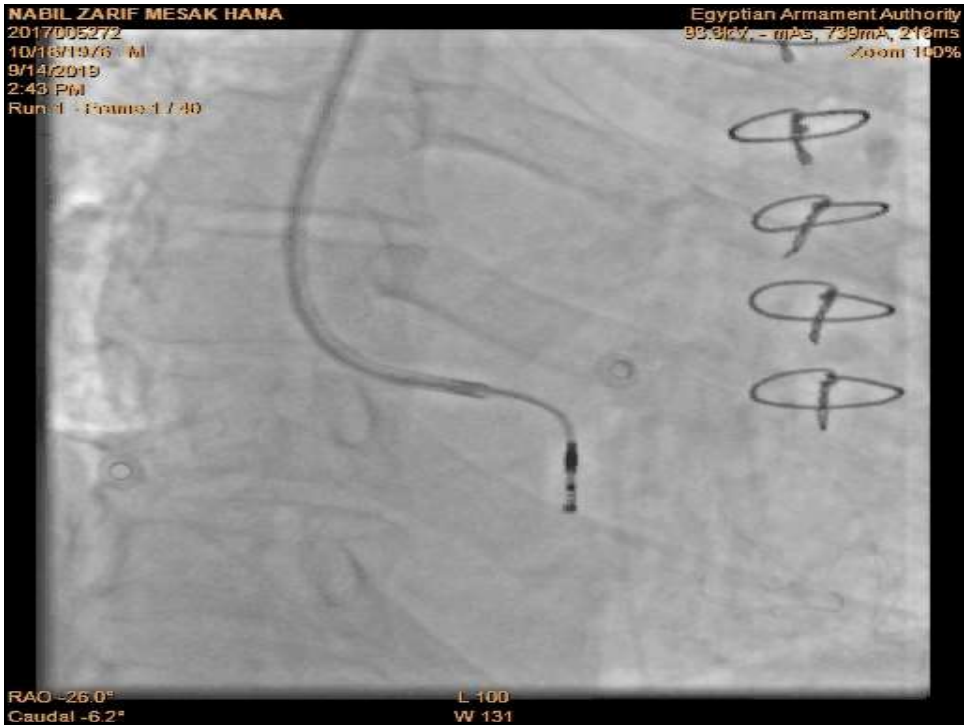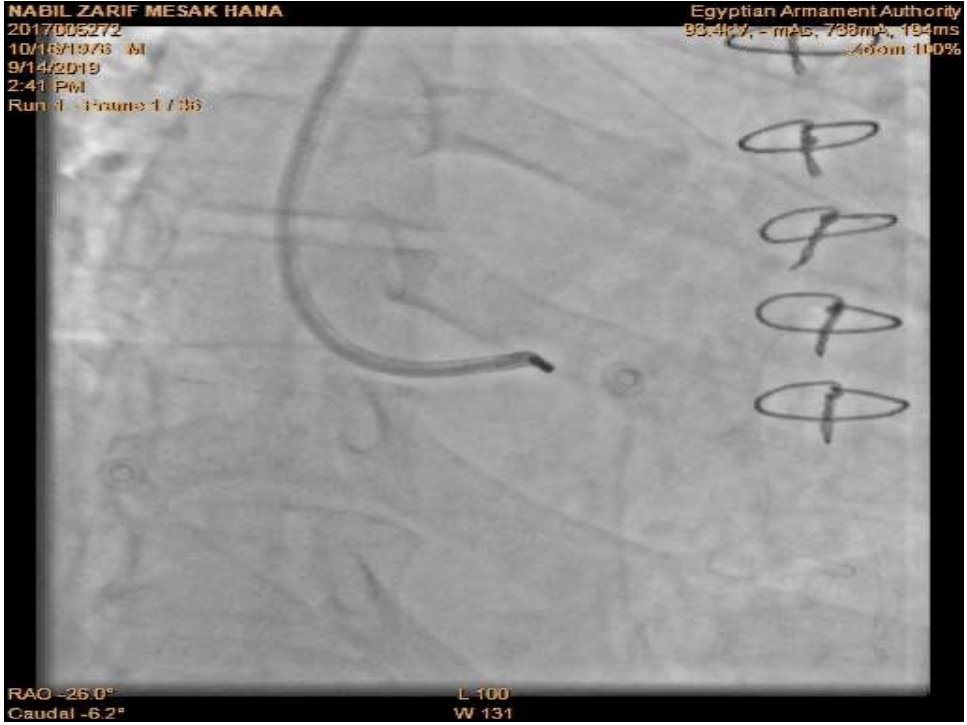In Cath-Lab

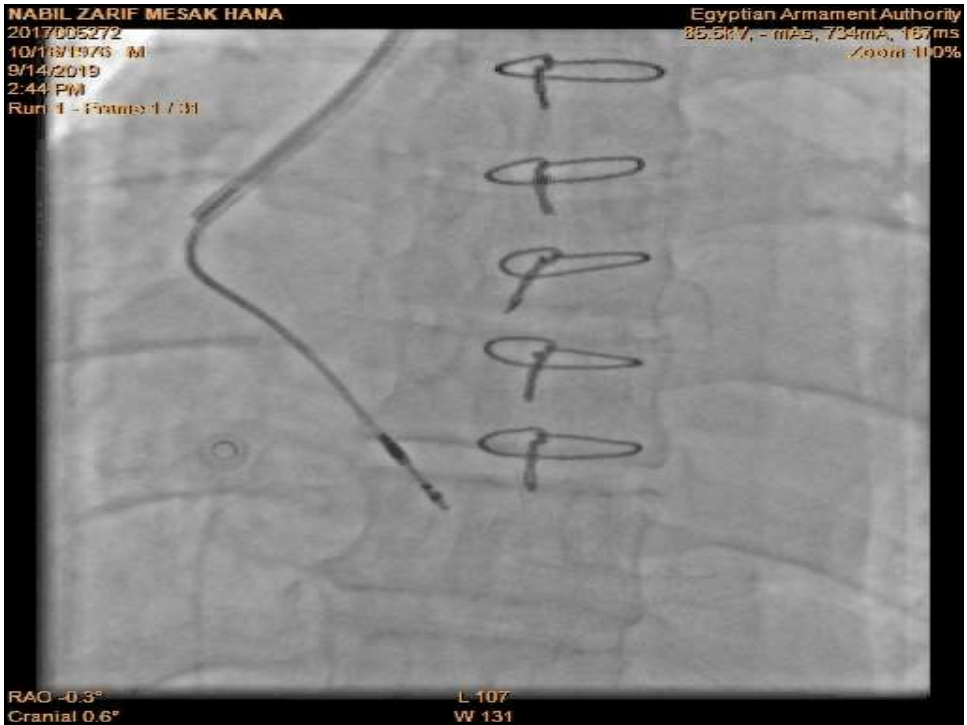
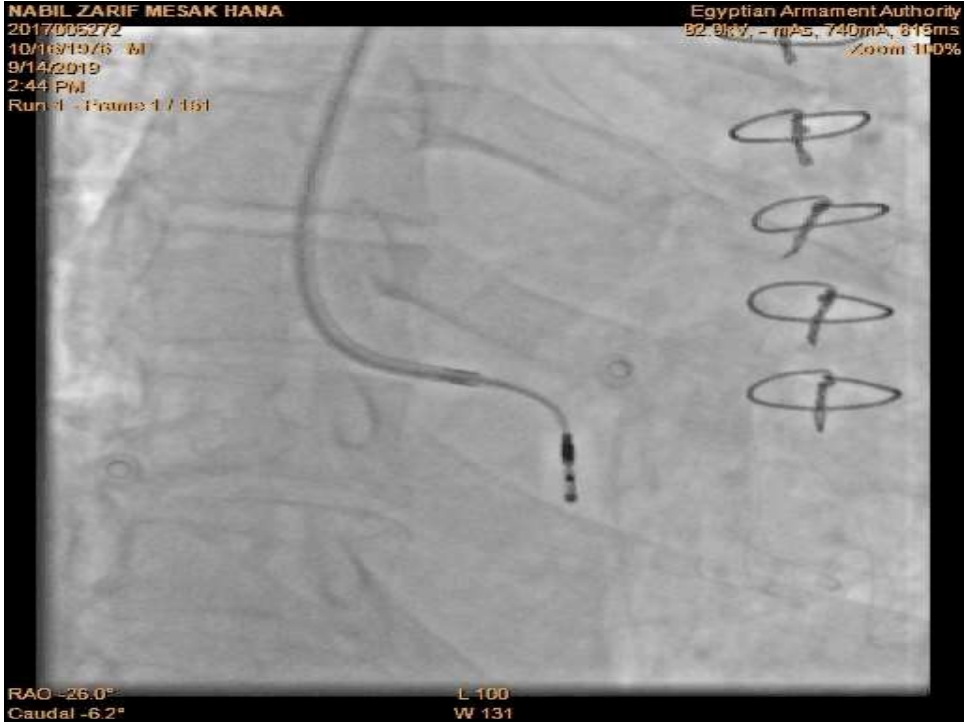
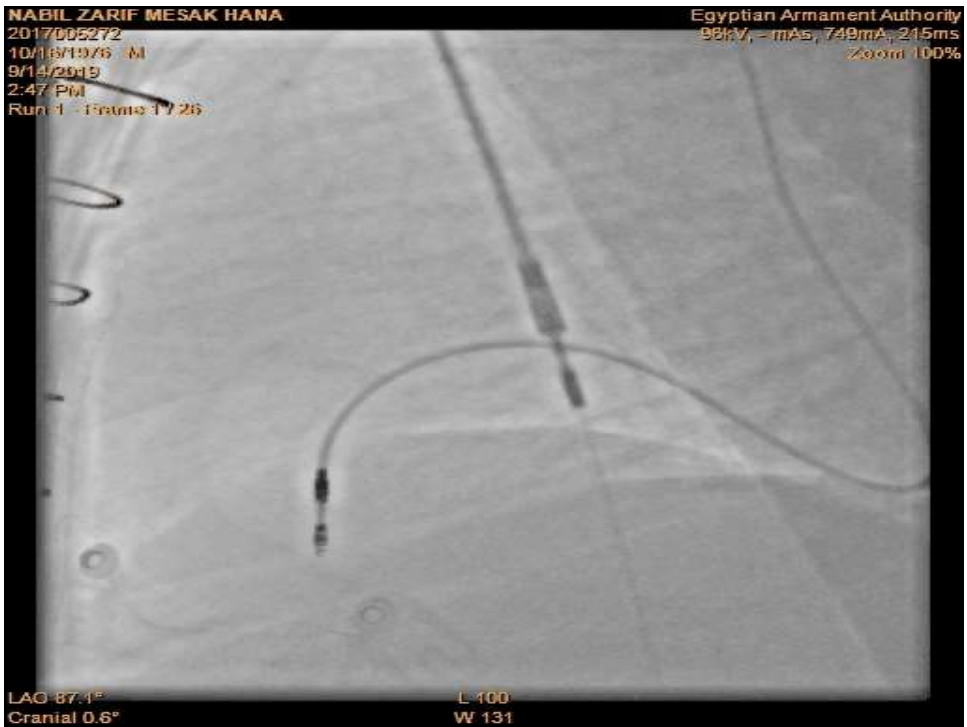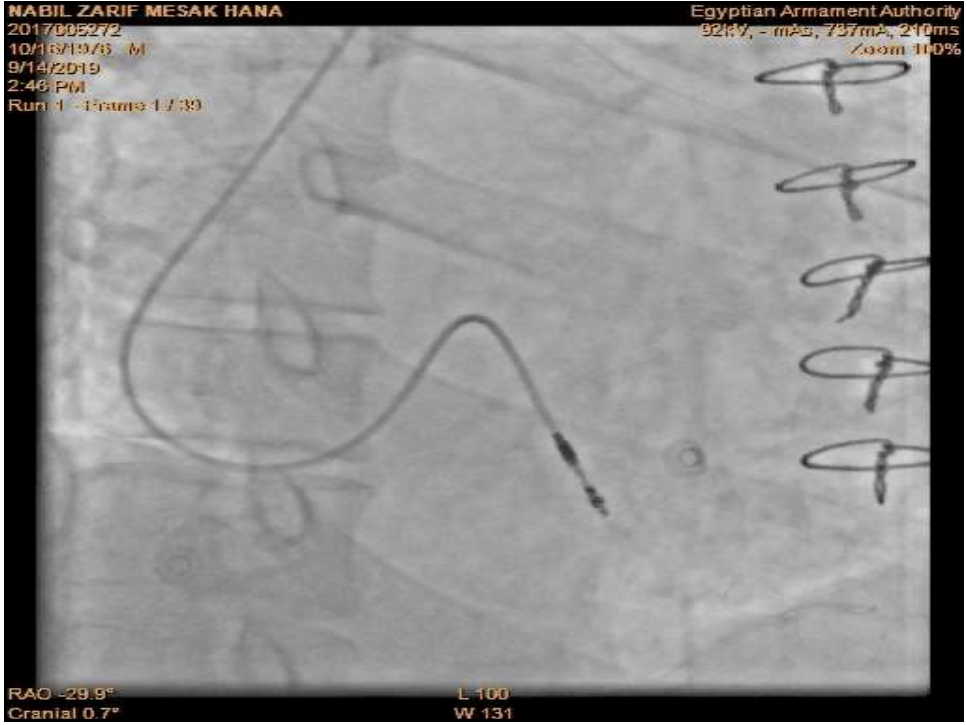Swan ganz catheter may help

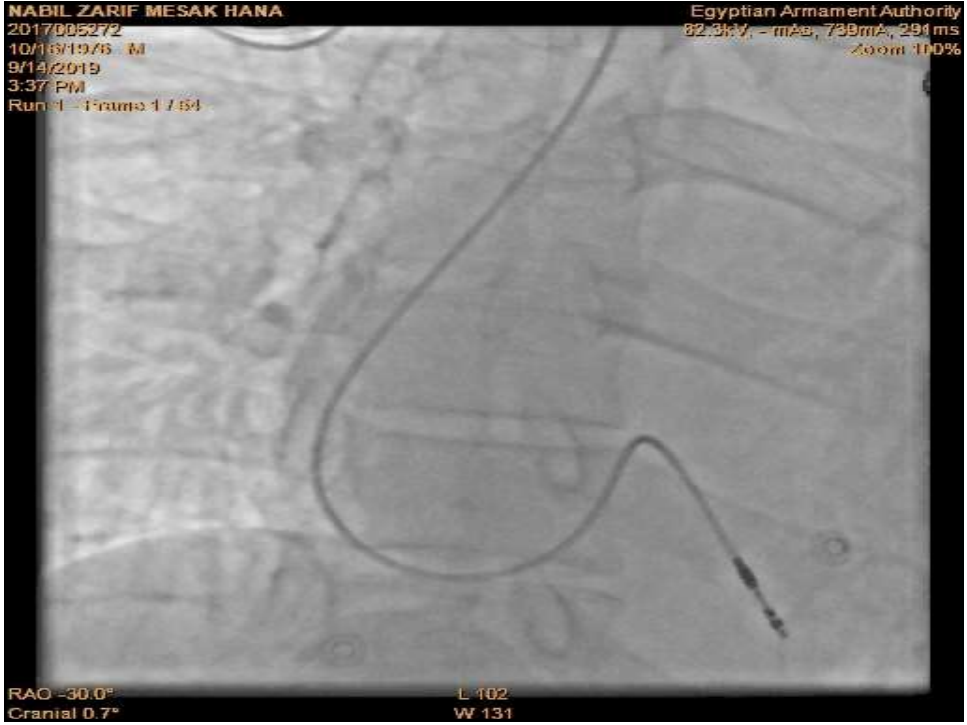



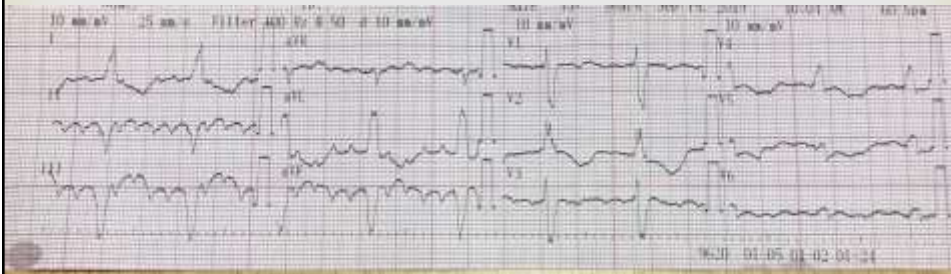








Post ECG



Post procedure



- ↳ Echo : no changes compared with pre-procedure
- ↳ Device interrogation: All parameters are very good

Thank you



- ↳ Thank you to our Teamwork:
 - Prof Dr. Mohammed Osama
Dean of NHI
 - Prof Dr. Azza Katta
 - Dr. Asmaa Abbady

